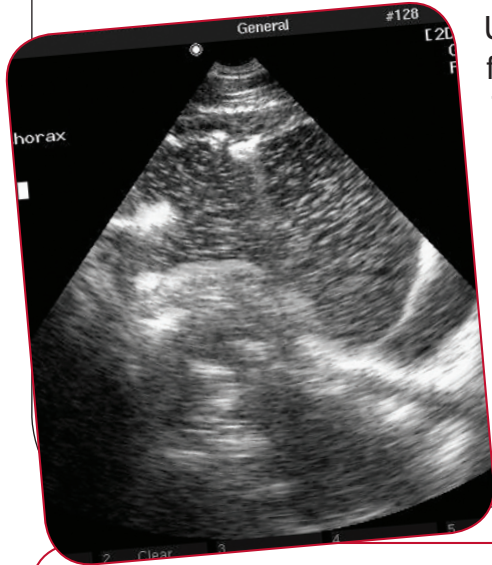


Abdominal and Thoracic Ultrasound



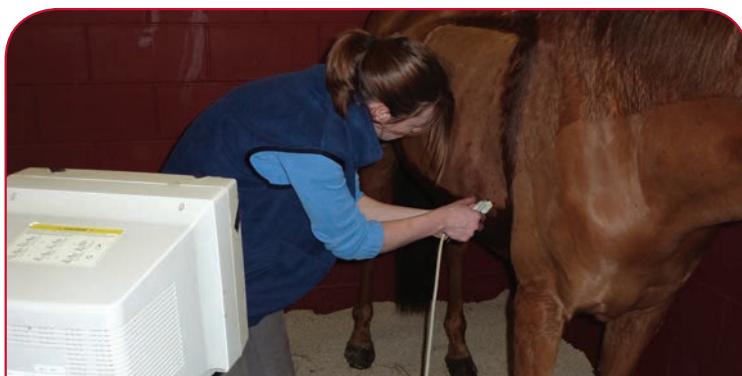Ultrasound is a non-invasive diagnostic technique that uses high frequency sound waves to image soft tissue structures in the body. The sound waves are translated into a black and white picture. With this technique it is therefore possible from the outside to investigate several disease processes in organs that are in the belly and the chest of the horse. Evaluation usually includes assessment of the location and size of an organ and changes in its tissue structure. In addition, in several organs (e.g. heart and kidney) blood flow can be visualised in a coloured picture using a technique called colour-Doppler ultrasound. Ultrasound can be used as an aid to pinpoint the location and depth of biopsy sites and needles.

Uses of abdominal ultrasound of the foal and adult horse:

- colic and colitis – evaluation of the location and appearance of large and small bowel;
- peritonitis – identifying infection and inflammation in the abdomen;
- kidney disease and urinary tract problems;
- liver disease;
- unexplained weight loss;
- bleeding in the abdomen;
- abscesses in the abdomen;
- cancers;
- evaluation of the unborn foal in the later stages of



ULTRASOUND GUIDED LIVER BIOPSY



ULTRASOUND EXAMINATION OF THE CHEST CAVITY

Uses of thoracic ultrasound of the foal and adult horse:

1. pneumonia and pleuritis – infection of the lungs and chest lining;
2. pneumothorax – collapse of the lung(s);
3. cancers in the chest cavity;
4. heart function – imaging of heart structures (e.g. the valves) and their function.

Benefits:

- non-invasive imaging of soft tissue structures;
- is performed in the standing (sedated) horse;
- can be performed during visits or in a clinic based setting;
- ultrasound guided biopsies.

Limitations:

- stronger machines and probes are needed than for rectal (pregnancy) ultrasound;
- to improve penetration of the sound waves into the body often clipping of the area of interest is needed;
- ultrasound is not perfect: penetration and picture quality depends on many factors including the size of the horse, body weight, obesity and location of the organ of interest.

Preparation for a scan

1. Depending on the length and thickness of the hair coat, clipping may be required. This could involve a large area of the chest and flanks depending on the area to be examined.
2. The skin is cleaned with an antiseptic solution to remove grease which interferes with the ultrasound waves.
3. Although the procedure is non-painful, sedation is sometimes used to help to keep the horse still.
4. The scan may be performed at your premises or at the clinic, depending on the portability of the machine used.



ULTRASOUND IS A USEFUL TOOL IN THE EVALUATION OF CONDITIONS OF THE ABDOMEN AND THORAX

SUMMARY

Ultrasound is a valuable tool to assess the abdomen and thorax of horses with:

1. critical illness;
2. signs of an acute abdomen problem (colic, colitis, peritonitis, bleeding);
3. signs of chronic and/or unexplained illness (cancers, abscesses, inflammatory disorders);
4. problems of the lungs and pleural surfaces;
5. heart problems;
6. monitoring foetal well being in late pregnant problem mares;
7. the need for collection of a tissue biopsy.

XLequine
Excellence in Practice

XLVets Equine is a novel and exciting initiative conceived from within the veterinary profession made up of independently owned, progressive veterinary practices located throughout the United Kingdom, members of XLVets Equine are committed to working together for the benefit of all their clients.

© XLVet UK Ltd.

No part of this publication may be reproduced without prior permission of the publisher.

For further information contact your local XLVets Equine practice: